

## Men 2 A Syndrome: Case Report

Ajitkumarkushwaha<sup>1</sup>, Pradeep Prasad<sup>2</sup>, Soni<sup>3</sup>

<sup>1</sup>(Surgical Oncology, NIMS, Hyderabad, Andhra Pradesh, India)

<sup>2</sup>(Biochemistry, RIMS, Ranchi, Jharkhand, India)

<sup>3</sup>(Pharmacology, MGM Medical College, Jamshedpur, Jharkhand, India)

---

**Abstract:** Type 2 A multiple endocrinal neoplasia is a rare familial cancer syndrome caused due to mutation in the RET proto-oncogene characterized by medullary carcinoma of thyroid, pheochromocytoma, parathyroid hyperplasia and occasionally cutaneous lichen amyloidosis and Hirschsprung's disease. RET is expressed in neuroendocrine cells, urogenital tract cells and branchial arch cells. All patients with MEN2A develop medullary carcinoma of thyroid, approximately half develop pheochromocytomas, and 30% develop hyperparathyroidism. 50% of those with RET mutation develop the disease by the age of 50 years, and 70% develop the disease by the age of 70 years. We report a case of 55 year lady with nephrocalcinosis, on evaluation was found to have left inferior parathyroid adenoma with raised calcium and PTH. USG neck also showed multiple nodules in thyroid. She was known hypertensive. During surgery for parathyroid adenoma, the left inferior parathyroid was found to be enlarged with small hard nodule in left lobe of thyroid along with few paratracheal lymph nodes. Left hemithyroidectomy with paratracheal lymph node dissection and excision of parathyroid adenoma was done. The final histopathology was medullary carcinoma thyroid p T1a N1a and left inferior parathyroid adenoma. Patient was further evaluated for MEN syndrome and was found to have bilateral pheochromocytoma with raised plasma meta-nephrine and raised pro-calcitonin. Patient underwent completion thyroidectomy and bilateral adrenalectomy. Histopathology was reported as bilateral benign pheochromocytoma. Patient is doing well with replacement dose of steroids. This case demonstrates that one should have high suspicion for diagnosing MEN syndrome. After 7 months of follow-up patient calcitonin, calcium and metanephrines level is normal.

**Keywords:** MEN2A, pheochromocytoma, parathyroid adenoma, RET

---

### I. Introduction

Multiple endocrinal neoplasia type 2 is a autosomal dominant inherited disorders. In 1961 Sipple reported high incidence of bilateral Pheochromocytoma in patient with thyroid malignancy<sup>1</sup>. Latter on hyperparathyroidism was also found to be associated with the syndrome. This syndrome of medullary carcinoma of thyroid, pheochromocytoma and hyperparathyroidism was initially termed as MEN-2, now it is called MEN-2A. Other features associated with this syndrome are cutaneous lichen amyloidosis and hirschsprung's disease<sup>2</sup>. The reported incidence is 1 case in per 30,000-50,000 in united states<sup>3</sup>. Underlying gene defect is in RET protooncogene( which encodes a tyrosine kinase receptor). Mutation in RET has been localized to 10q11.2 in MEN 2. The protein produced by RET is critical during embryonic development of enteric nervous system and kidneys. Studies from individuals in families with MEN-2A have been able to predict the inheritance of of MEN-2A by detection of of miss sense mutation in RET. These mutation can be classified as to their risk of aggressive MTC, based on genotype phenotype correlation studies<sup>1</sup>. 50% of the patient will present by the age of 50 years and 70% by the age of 70 years<sup>3</sup>.

Medullary carcinoma of thyroid arises from the parafollicular cells (C) cells. These are calcitonin secreting cells. Medullary carcinoma thyroid is most malignant in MEN-2B, malignant in MEN-2A, least virulent in familial MTC. Prophylactic thyroidectomy in infancy for patient with high risk RET mutations or by age of 5 years in children with an identifiable RET mutation is recommended due to nearly complete penetrance of the gene. Nearly treatment can prevent death in MEN-2A patients. 42% to 60% of patient in MEN-2A develop pheochromocytoma. Pheochromocytoma usually presents by the second or third decade of life and are often bilateral. Size of the tumor is usually less than 3cm. Pheochromocytoma in MEN-2A or MEN-2B are seldom malignant and are usually within the adrenal gland. Early detection can prevent hypertensive crisis. Adrenalectomy is advised in patient with biochemical confirmation of pheochromocytoma. Bilateral adrenalectomy is reserved for bilateral adrenal masses. 35% of patient develop primary hyperparathyroidism in MEN-2A and are usually multiple gland disease. However it is usually less clinically significant and causes fewer symptoms<sup>1</sup>.

### Presentation:

Usually the presenting symptom in MEN-2A are hypertension, episodic sweating, diarrhea (due to elevated prostaglandin or calcitonin levels), pruritic skin lesion (cutaneous lichen amyloidosis) in scapular area of back, or with neck swelling. Patient with hypercalcemia presents with constipation, polyuria, polydipsia, depression, nephrolithiasis, glucose intolerance, GERD. Physical examination may reveal thyroid enlargement, lymphadenopathy, hypertension.

The patients are worked up with biochemical test like serum calcitonin ( pentagastrin stimulation test), serum calcium, PTH levels, 24 hrs urine calcium, urinary catecholamines and metanephrine. Imaging studies includes ultrasonogram of neck, CT or MRI for adrenals. MIBG scan are useful for localizing pheochromocytoma. Radionucleotide scanning like octreo scan can be used to detect spread in medullary carcinoma thyroid. Invasive test includes the fine needle aspiration of the thyroid nodule or lymph nodes. Genetic testing to identify RET mutation is done .if a mutation is identified then family members are also screened.

## II. Case report :

### 55yr old female presented in the outpatient department with complaints of generalised body ache.

- She was a known case of nephrocalcinosis on medical management. On evaluation was found to have parathyroid adenoma
- k/c/o hypertension on beta blockers
- No h/o chronic illness like diabetes, pulmonary tuberculosis, asthma.
- History of some thyroid surgery present 18yrs back (no details)
- History of hysterectomy 12yrs back

On examination scar was present in neck. Thyroid normal, no lymphadenopathy. Abdominal examination was essentially normal except for the presence of hysterectomy scar.

Patient was worked up with following investigations :

#### • Blood investigations:

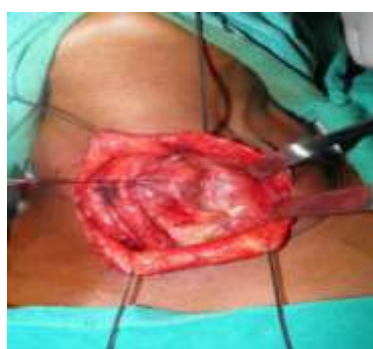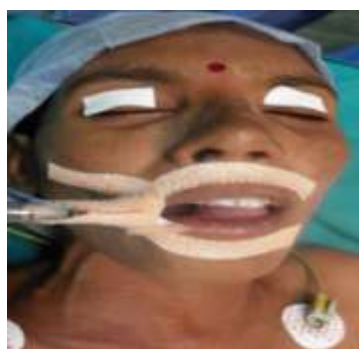serum calcium 12.6; serum PTH 432.

TFT: normal limit.

ALP 458 u/ltr.

- 2D Echo and ECG normal.
- USG neck: multiple nodules in thyroid gland. Well defined hypoechoic lesion with increased vascularity seen in lower pole left thyroid gland likely parathyroid adenoma.
- PTH scan: left inferior parathyroid adenoma.
- USG abdomen: nephrocalcinosis.

Patient was diagnosed to be a case of parathyroid adenoma and was planned for left inferior parathyroid gland excision. Intra-op findings were 2\*2 cm left inferior parathyroid adenoma hard nodule in upper pole of left thyroid small para tracheal lymph nodes normal right lobe of thyroid left superior parathyroid not identified Patient was discharged after 5 days



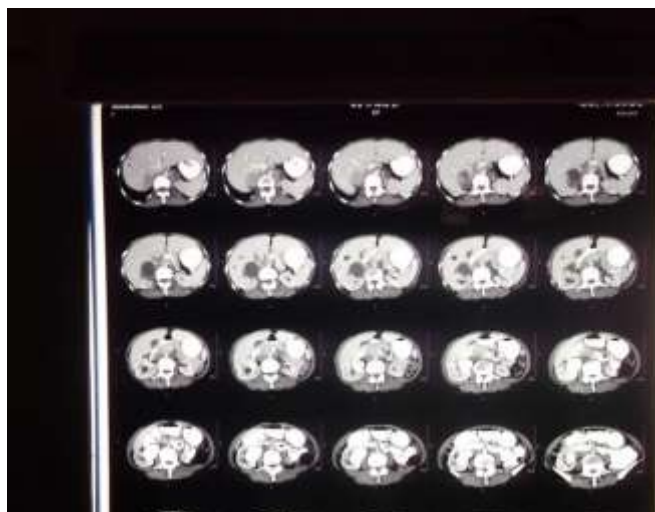
**Histopathology :** Medullary carcinoma thyroid T1a N1a Left inferior parathyroid adenoma. Subsequently patient was worked up for MEN syndrome

**Urinary VMA :** negative

**Serum procalcitonin :** 17 (raised)

**X ray skull:** normal

CECT abdomen: **bilateraladrenalmass** lesion s/o pheochromocytoma. Bilateral nephrocalcinosis. Large right side stag horn calculus with hydronephrosis. Multiple liver cyst.



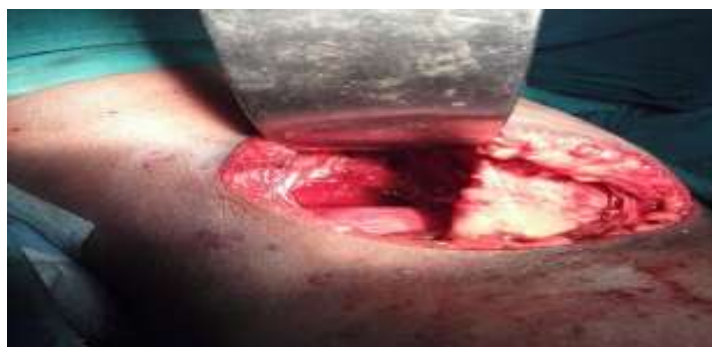Patient diagnosed to be a case of MEN-2A and was planned for completion thyroidectomy and bilateral adrenalectomy.

Patient underwent completion thyroidectomy Intra operatively right lobe of thyroid was found to be normal 2.5\*2.5cm without any nodules.Histopathology revealed no e/o malignancy.Post operatively patient was started on replacement dose of eltroxin 200 mg.Patient was put on tab prazosin 2.5mg and tab betaloc 12.5 mg. with adequate hydration and alfa and beta blockade patient was taken for right adrenalectomy.

Intraoperatively right adrenal mass 9\*6\*6 cm solid cystic lesion adherent to the IVC

Post op Histopathology was pheochromocytoma.

IHC: chromgtafin Positive Ki 67 – 2 %.



RET proto-oncogene study was sought for but not done due to financial problems.Patient was on regular follow upMetanephrine level after 2 months was raised (1520)General medicine consultation taken up for replacement dose of steroidsPatient underwent left adrenalectomy after 5 months, with intra-operative steroid i.v replacement

Intra-operatively 4\*3\*3 cm left adrenal tumor. On handling the tumor there was fluctuation in blood pressure.Post operatively patient was put on IV steroid.On 3<sup>rd</sup> post op day oral tab wysolone 10mg b.d; tab florinal 100mg o.d

**Final histopathology** – pheochromocytoma.

Post op follow up 04-05-2014 TSH- 0.6, S.Calcitonin-normal limit .Usg abdomen B/L NephrocalcinosisNow patient is on eltroxin 200 mg OD, Wysolone 5mg OD, Florinal 100 mg OD Patient is on follow up for past 8 months and she is doing well.

### **III. Discussion**

MEN-2A is a rare autosomal dominant endocrine disorder and it requires high index of suspicion to diagnose these cases. Patient should be worked up with proper biochemical and radiological investigations. Evaluation for pheochromocytoma is important because these should be removed before other surgical

interventions. Pre operatively patient with pheochromocytoma should be prepared with adequate alpha-adrenergic receptor blockade. Phenoxybenzamine should be administered 1 to 2 weeks before surgery, starting with a dose 10 mg twice daily and increased to usual dose of 10 to 20 mg three times daily. The end point is normotension with mild to moderate asymptomatic postural hypotension (15mm Hg ). Beta blocker is usually reserved for those with sinus tachycardia<sup>1</sup>.

Patient presenting with hypercalcemia should be adequately hydrated, after which they should be treated with furosemide. Calcitonine, glucocorticoids or bisphosphonates can also be used, to lower the serum calcium level ideally below 14 mg/dl<sup>4</sup>.

The symptoms of diarrhea can be controlled with prostaglandin inhibitors.

Medullary carcinoma thyroid should be treated with total thyroidectomy with central neck dissection. The need for unilateral or bilateral modified neck dissection is controversial. Children often do not require node dissection, because their disease is at hyperplasia stage and has not reached metastatic potential<sup>3</sup>. Patient who are not surgical candidates may benefit from tyrosine kinase inhibitors like vandetanib.

Parathyroid surgery involves removal of the grossly abnormal parathyroid gland to prevent post operative hypocalcaemia as hyperplasia is the usual presenting feature. Thymectomy is done to remove if any supernumerary parathyroid gland.

Patient with MEN-2A may not present with bilaterally enlarged adrenal gland at the same time, in such case a unilateral adrenalectomy is performed to reduce the risk of Addisonian crisis. Those with bilateral disease subtotal adrenalectomy to preserve the adrenal cortical function may be performed. Small risk for recurrence is there with this procedure. For those not fit for surgery Metirosine (tyrosine hydroxylase inhibitor) can be considered.

Since the initial abdominal ultrasonogram did not reveal any adrenal abnormality so we thought it to be a case of parathyroid adenoma. patient was hence put for parathyroid gland excision. But after the histopathology report MEN-2A was diagnosed and patient was treated with completion thyroidectomy and bilateral adrenalectomy.

Post operatively patient need thyroid hormone replacement, along with calcium/vitamin D supplementation. Corticosteroid and mineralocorticoid fludrocortisone are used in combination for patient suffering from adrenocortical insufficiency.

#### **IV. Conclusion**

In patient with MEN-2A medullary carcinoma thyroid is most lethal disease. Survival of the patient depends upon the extent of medullary carcinoma of thyroid at the initial surgical resection. After adequate surgery patient can be followed with serum calcitonin levels. Detection of an elevated plasma calcitonin level or abnormal response with pentagastrin indicate recurrent or persistent disease. The appropriate management of metastatic MTC or recurrent MTC is less studied. Because of the indolent nature of the tumor most choose not to aggressively treat the metastatic disease, but rely on local treatment. Local therapy includes surgery or radiation treatment. In patient with MEN-2A, the medullary carcinoma of thyroid is well tolerated. The average life expectancy of patient with MTC and MEN-2A is more than 50 years.

If recurrent hypercalcemia is suggested then repeat cervical exploration is considered.

Patient should be evaluated after every 6 months. During these evaluation patient should undergo physical examination, 24-hour urine catecholamine, metanephrine and VMA, CEA level, calcitonin and serum calcium testing.

With timely follow up and careful evaluation these patient have long life expectancy.

#### **References**

- [1]. Devita ,hellman, and rosenberg's principles of oncology
- [2]. LIC - Sabiston Textbook of Surgery: The Biological Basis of Modern Surgical practice
- [3]. By Courtney M. Townsend Jr., R. Daniel Beauchamp, B. Mark Evers, Kenneth L. Mattox
- [4]. MelanieL Richards, MD; Chief Editor: George T Griffing, Type 2 multiple endocrine neoplasia overview, updated 11 december, 2015 , Medscape
- [5]. Bilezikian JP. Clinical review 51: Management of hypercalcemia. J Clin Endocrinol Metab 1993; 77:1445.